



PATIENT

Barkley Baptise

SPECIES

Canine

BREED

Poodle Mix

SEX

Male Neutered

AGE

7 years

WEIGHT

37lbs

INTERPRETED BY

Maggie Machen Lamy,
DVM, DACVIM
(Cardiology)

IMAGING PERFORMED BY

Val Shumskaya

HOSPITAL NAME

Englewood Vet
Center

REFERRING VET

Dr. Ezik

INVOICE

29533

DATE

3/10/23

PRESENTING CLINICAL SIGNS

History: Recheck echo. Assess prior to anesthesia.

-Pertinent previous echo findings (9/2022 MML): Mild MR, no LA or LVE, trace TR: 2.2m/s. LA: 2.1, LV: 3.2.

ECHOCARDIOGRAM FINDINGS

2D, m-mode, color flow and doppler imaging is available. Mild diffuse thickening of mitral valve leaflets with no prolapse into the left atrial lumen. Mild mitral regurgitation with no left atrial dilation. Normal LV diameter with adequate myocardial function. The tricuspid valve appears normal with trace tricuspid regurgitation. Normal right atrial and ventricular diameter and morphology indicating no overt evidence of pulmonary arterial hypertension. The pulmonic and aortic valves are normal in morphology and mobility. Normal pulmonic and aortic outflow velocities with laminar flow. No obvious aortic or pulmonic insufficiency. No pericardial or pleural effusion noted. No obvious cardiac masses.

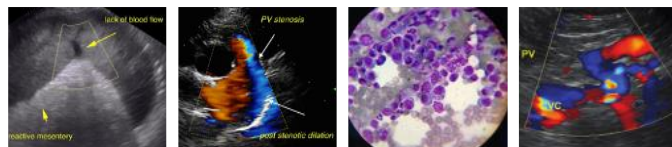
CARDIAC CHART

CANINE CARDIAC PARAMETERS	MR VMAX (m/s)	TR VMAX (m/s)	LA/AO (Boon method)	LA/AO (Heart Base; Swe)	FS (%)	EF (%)	EPSS (cm)
NORMAL PARAMETER	4.5-5.5	<2.7	1.3	<1.6	28-40	40-100	<0.6
PATIENT	NM	NM	1.5	1.3	31	60	NM
CANINE CARDIAC PARAMETERS	HR (BPM)	AV VMAX (m/s)	PV MAX (m/s)	BODY WEIGHT (kg)	LA 2D short axis Base view (cm)	LVIDd Avg; 2D and m-mode short axis (cm)	LVIDs Avg; 2D and m-mode short axis (cm)
NORMAL PARAMETER	50-100	0.7-1.7	0.7-1.6	BELOW	BELOW	BELOW	BELOW
PATIENT	150	1.5	0.95	16.8	2.3	3.5	2.4
*Normal chamber parameters expressed as a mean value (SD)							
BODY WEIGHT DEPENDENT PARAMETERS							
<i>*Note: All measurements based upon multi-modal images and methods. An average value is reported.</i>							
	3	1.27 (5.3)	2.46 (2.46)	1.36 (5.5)			
	5	1.40 (4.5)	2.74 (5.2)	1.60 (4.7)			
	10	1.50 (3.8)	3.27 (3.5)	2.06 (3.1)			
	15	1.83 (2.0)	3.71 (2.4)	2.43 (2.1)			
	20	2.02 (1.9)	4.14 (2.2)	2.80 (2.0)			
	25	2.18 (2.4)	4.48 (2.9)	3.10 (2.5)			
	30	2.33 (3.3)	4.83 (3.9)	3.39 (3.4)			
	35	2.48 (4.3)	5.17 (5.0)	3.69 (4.5)			
	40	2.62 (5.2)	5.48 (6.1)	3.96 (5.4)			
	50	2.88 (7.1)	6.07 (8.3)	4.46 (7.4)			

INTERPRETATION OF THE FINDINGS & FURTHER RECOMMENDATIONS

Chronic degenerative valve disease causing mild mitral and trace tricuspid regurgitation persists with evidence of stability. The left and right heart dimensions are stable with no pulmonary hypertension or other issues have developed. Lack of significant left atrial enlargement indicates the current risk for complication is low.

Given these findings, no cardiac medications are clearly indicated. Assessment of progression in the future will help predict long term prognosis, which is highly variable at this stage (B1). Omega



PATIENT

Barkley Baptise

fatty acid supplementation and mild salt restriction may be of some long-term benefit. Monitor for development of a cough, labored breathing, exercise intolerance or collapse episodes.

SPECIES

Canine

Anesthetic risk is considered mild if needed. Cardiac protective drug choices (opioid/benzodiazepine premedication, propofol or alfaxalone induction, isoflurane gas) are recommended. Pre-oxygenate for 5-10 minutes prior to induction. Monitor for arrhythmias, hypotension, and hypoxia both intra and post-operatively and intervene as necessary. Mild IV fluid restriction is recommended to avoid fluid overload. Avoid heart rate stimulating drugs such as atropine unless clinically indicated.

BREED

Poodle Mix

Recommend conservative monitoring with a recheck echocardiogram in 1 year, sooner if any development of clinical signs.

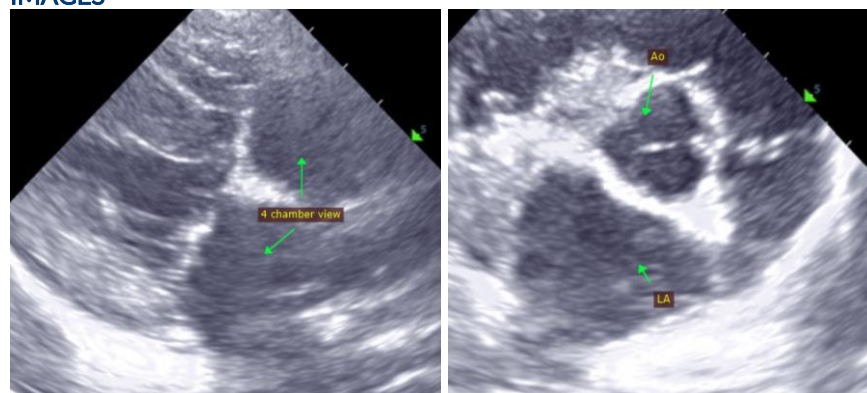
SEX

Male Neutered

AGE

7 years

IMAGES



WEIGHT

37lbs

The information and recommendations provided are based on the images presented by the referring veterinarian. No evaluation can be communicated regarding pathology that was not visible in the image/video clips provided.

INTERPRETED BY

Maggie Machen Lamy,
DVM, DACVIM
(Cardiology)

Thank you for this referral. This report was generated using transcription software, and minor dictation errors may be present. If the clinical or image interpretation does not parallel your findings or if I can be of any further assistance, please contact me.

IMAGING PERFORMED BY

Val Shumskaya

Maggie Machen Lamy, DVM
Diplomate of the American College of Veterinary Internal Medicine (Cardiology)
info@sonopath.com

HOSPITAL NAME

Englewood Vet
Center

REFERRING VET

Dr. Ezik

INVOICE

29533

DATE

3/10/23